

QUICK REFERENCE GUIDE

Treatment of meniscal lesions and isolated lesions of the anterior cruciate ligament of the knee in adults

June 2008

AIM OF THE GUIDELINES

To encourage good practices in the areas of meniscal surgery (particularly meniscus preservation) and anterior cruciate ligament (ACL) reconstruction surgery in adults (mature bones).¹

KEY POINTS

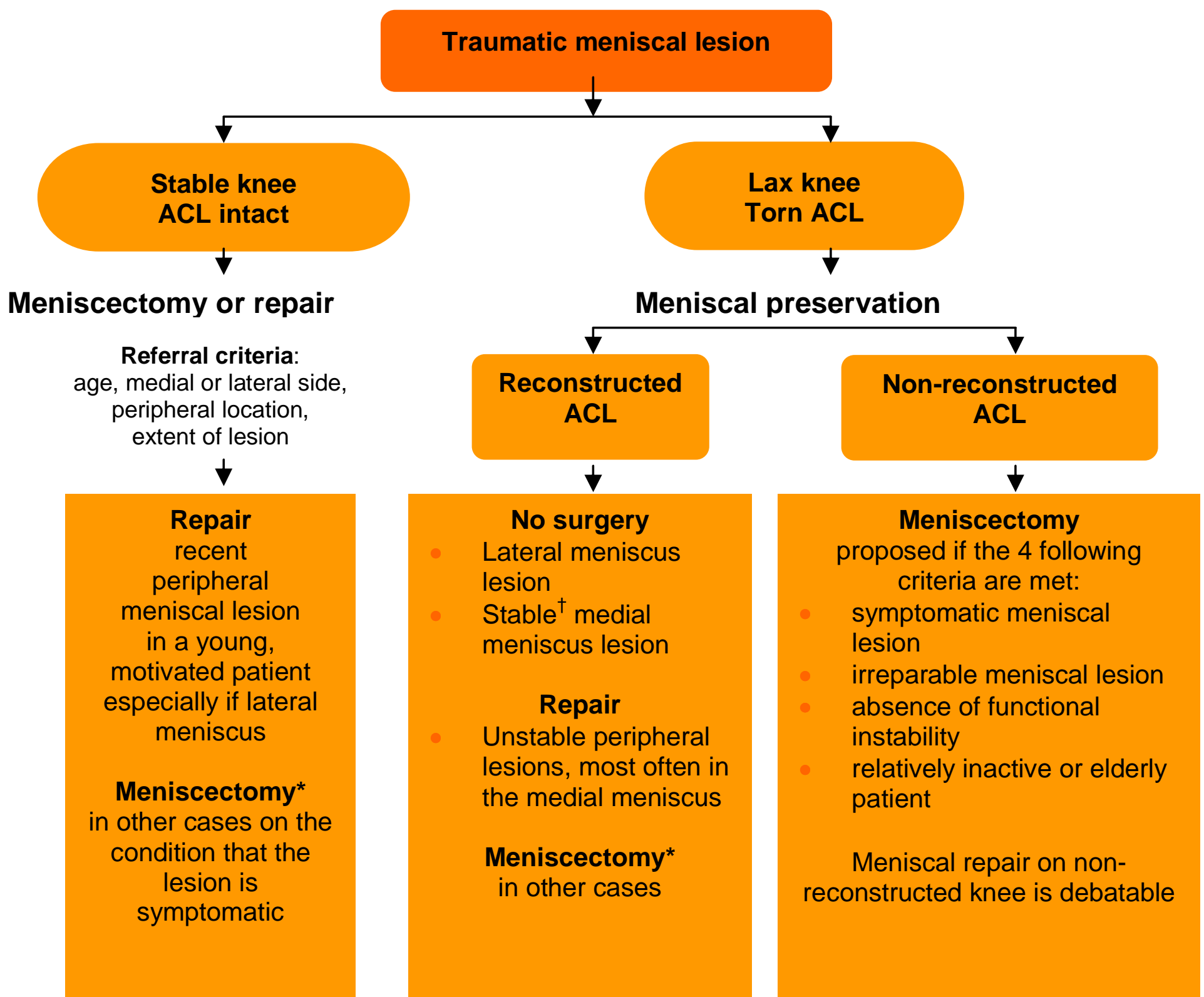
- All meniscectomies should be carried out by arthroscopy.
- Meniscal lesions do not necessarily warrant meniscectomy.
- No surgery or meniscal repair should always be considered.
- Not all ACL lesions require reconstructive surgery.
- Functional instability is the key symptom indicating ACL reconstruction.
- Delayed ACL reconstruction is advisable to reduce thromboembolic complications or stiffness.
- Bone-tendon-bone and hamstring tendon reconstruction give similar results.
- Lateral tenodesis should be limited to special cases.

¹ Companion guidelines on ‘Criteria for choosing rehabilitation after-care following anterior cruciate ligamentoplasty of the knee: Inpatient or outpatient care?’ have been published in French and English on the HAS website (HAS January 2008).

MENISCAL REPAIR

- Meniscal repair can only be used to heal peripheral meniscal lesions affecting healthy meniscal tissue (injury) in vascularised areas (red-red zone or red-white zone).
- If surgery is indicated for such peripheral lesions, the alternative to repair is total or subtotal meniscectomy of the segments concerned. However, this damages the cartilage.
- The current trend is towards the use of hybrid implants (fixation material combined with suture wire) and an exclusively arthroscopic technique.
- Complications such as neuropathic pain, which prevail after techniques requiring a posterior approach, limit these open surgery techniques to cases of absolute necessity.

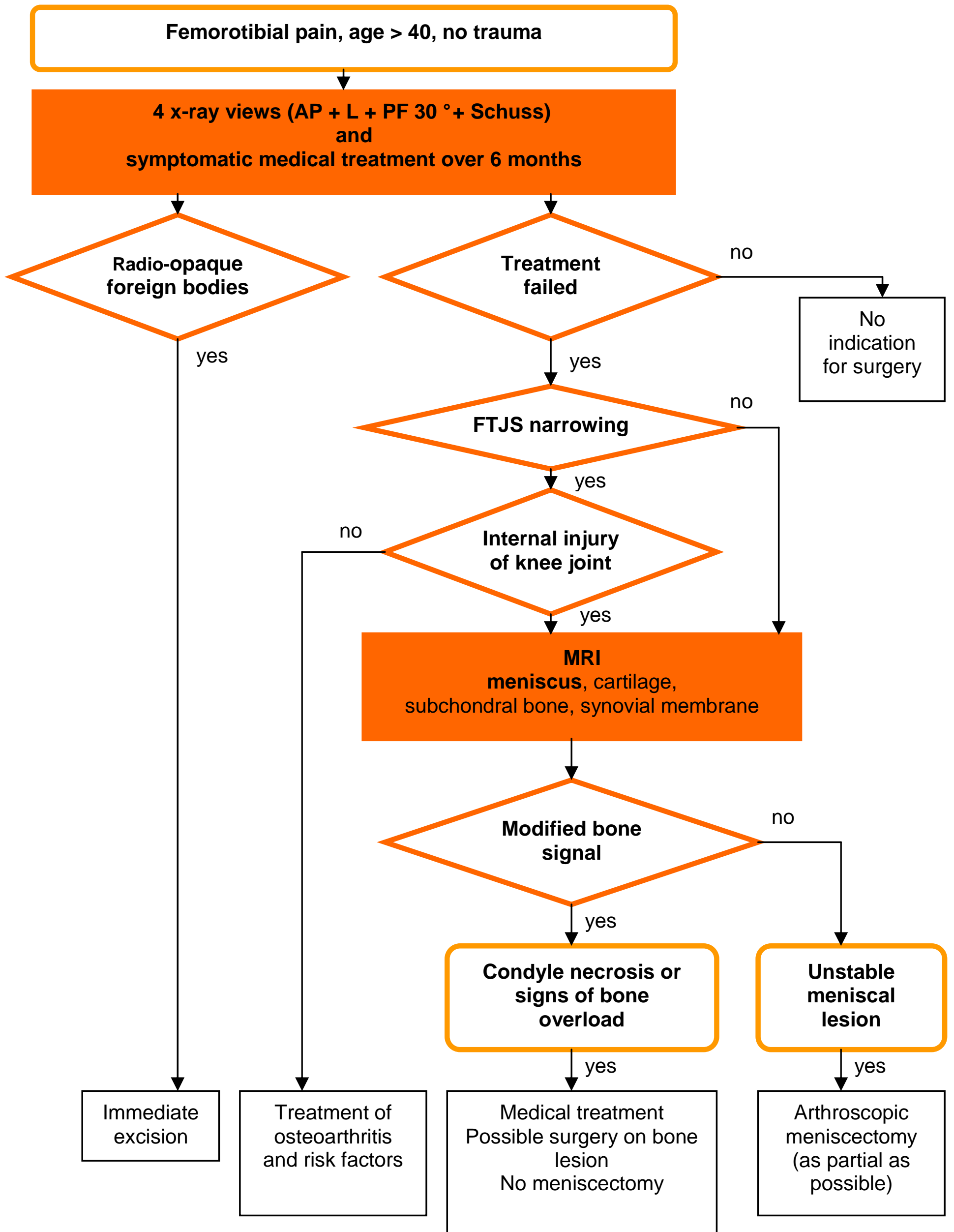
MANAGEMENT OF TRAUMATIC MENISCAL LESION



*: as partial as possible

†: a meniscal lesion is said to be stable when, upon arthroscopic traction of the palpation hook, it does not exceed the lower end of the femoral condyle

DIAGNOSTIC AND THERAPEUTIC MANAGEMENT OF A NON-TRAUMATIC MENISCAL LESION



FTJS: femorotibial joint space

ANTERIOR CRUCIATE LIGAMENT RECONSTRUCTION

ACL reconstruction should be performed by arthroscopy, given the possibility of assessing the joint fully, shorter post-operative recovery, decrease in morbidity, and fast recovery.

Choice of graft

- There are no prospective comparative studies that allow conclusions on the use of the quadriceps tendon or the fascia lata.
- Bone-patellar tendon-bone (BPTB) and hamstring tendon (HT) grafts provide similar results.
- Anterior pain (tendon or neuropathic pain) and flexum are more common with BPTB than with HT grafts but the recovery level in terms of sports is similar for both techniques. However, anterior pain can have professional consequences (occupations requiring kneeling down)

Choice of fixation

Bone-patellar tendon-bone reconstruction

- Fixation by a femoral interference screw and a tibial interference screw is the benchmark technique.
- Double fixation to the femur or tibia is unnecessary, except where the interference screw does not hold well (particularly on the tibia).
- The screw may be metal or bioresorbable polylactic acid (PLA).
- Bioresorbable screws offer the advantage of facilitating postoperative MRI readings and repeat surgery if necessary.

Hamstring tendon reconstruction

- In the femur, an extra-anatomical system, interference screw or any other intra-canal system can be used. No studies have shown evidence that a double femur fixation should be recommended.
- In the tibia, the traction is created in the axis of the graft. A double or reinforced fixation may therefore be proposed, particularly if the bone does not hold well.

Lateral tenodesis

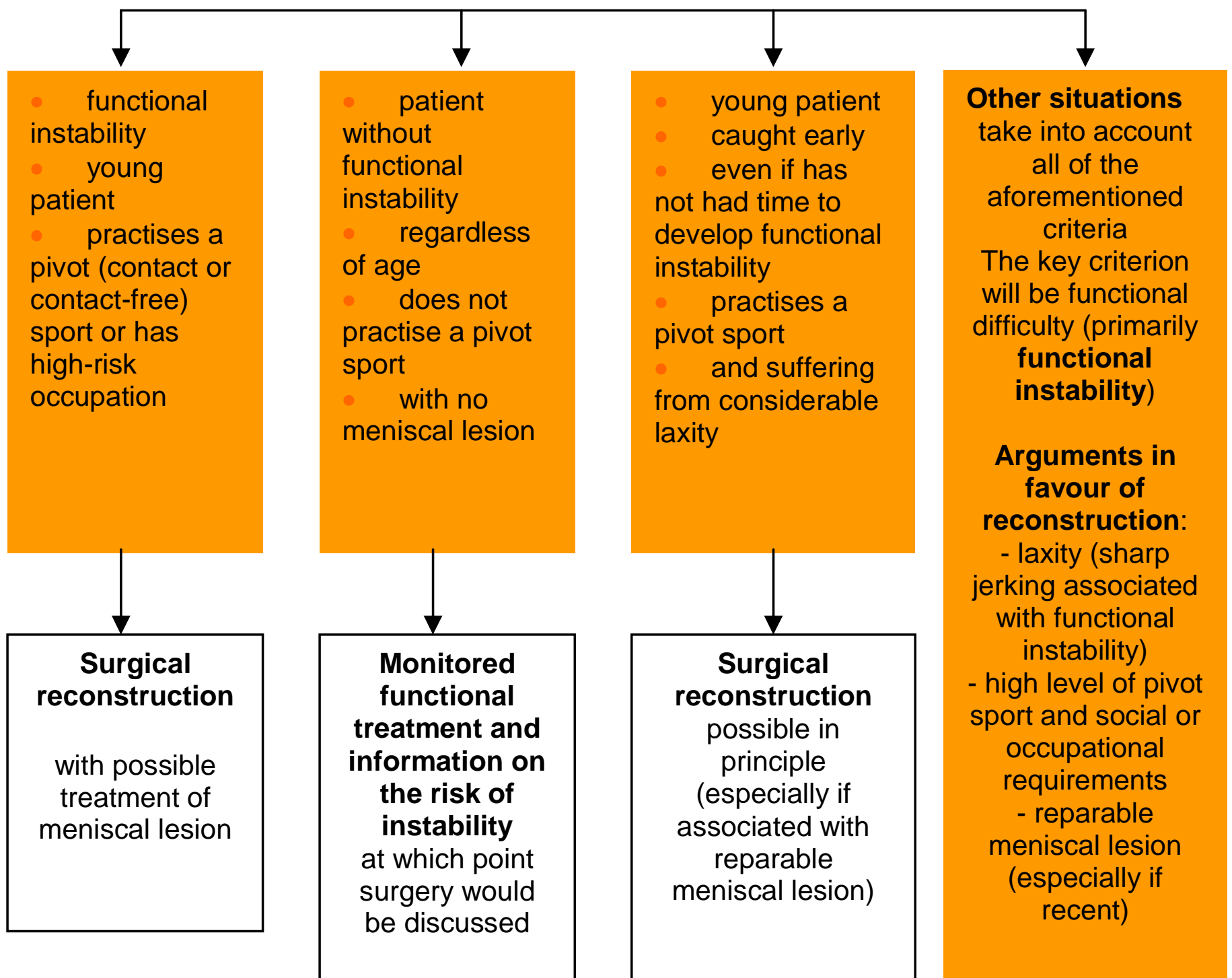
- Regardless of patient age, lateral tenodesis in isolation is not recommended.
- There is no indication for systematically combining lateral tenodesis in cases of chronic anterior laxity.
- Lateral tenodesis combined with intra-articular reconstruction should only be considered in the event of general anterior laxity.

INDICATIONS FOR ACL RECONSTRUCTION IN ADULTS

Torn ACL

Referral criteria: Functional instability

Age, type and level of sports, age of lesion, extent of laxity, presence of meniscal or cartilage lesions, social and occupational needs



HAS

This document presents the key points of the clinical practice guideline: 'Treatment of meniscal lesions and isolated lesions of the anterior cruciate ligament of the knee in adults' - Clinical practice guideline – Validated by the HAS Board in June 2008. The guideline and the scientific evidence review may be consulted in full on www.has-sante.fr